A 28-year-old man comes to the office to discuss hair loss. He has hair loss primarily around the temples, which began insidiously 3 years ago. The patient is concerned because several of his family members became almost completely bald by their late 30s. He otherwise feels healthy and has normal muscle strength, libido, and erectile function. The patient is married, has 2 children, and works as a charter airplane pilot. Physical examination shows moderate thinning of hair at the anterior scalp, temporal region, and vertex. An oral medication is prescribed to treat the hair loss. After the initiation of therapy, which of the following changes would most likely occur in this patient?

	Testosterone	Dihydrotestosterone	Estradiol
A.	Decreased	Decreased	Decreased
B.	Decreased	Decreased	Increased
C.	Decreased	Increased	Increased
D.	Increased	Decreased	Increased
E.	Increased	Increased	Decreased

Submit

A 28-year-old man comes to the office to discuss hair loss. He has hair loss primarily around the temples, which began insidiously 3 years ago. The patient is concerned because several of his family members became almost completely bald by their late 30s. He otherwise feels healthy and has normal muscle strength, libido, and erectile function. The patient is married, has 2 children, and works as a charter airplane pilot. Physical examination shows moderate thinning of hair at the anterior scalp, temporal region, and vertex. An oral medication is prescribed to treat the hair loss. After the initiation of therapy, which of the following changes would most likely occur in this patient?

	Testosterone	Dihydrotestosterone	Estradiol
A. (3%)	Decreased	Decreased	Decreased
B. (10%)	Decreased	Decreased	Increased
C. (5%)	Decreased	Increased	Increased
✓ D. (67%)	Increased	Decreased	Increased
E. (13%)	Increased	Increased	Decreased

Omitted
Correct answer
D

67%
Answered correctly

03 secs
Time Spent

03/27/2020
Last Updated

Explanation

Androgenetic (male pattern) alopecia in men	
Pathophysiology	• Genetic factors + androgen (dihydrotestosterone) effect • Shortened anagen phase • Follicular miniaturization
Clinical features	• Onset at puberty, progressive course • Hair loss at temporal, frontal, vertex scalp • Shorter, thinner, sparser hair
Treatment	• Minoxidil • 5-alpha reductase inhibitors (eg, finasteride)

This patient has **androgenetic alopecia** (often called male pattern hair loss), which presents with **progressive hair loss** at the temples, frontal hairline, and vertex. Androgenetic alopecia is characterized by a shortened anagen hair growth phase in the affected portions of the scalp, leading to shorter, thinner hair shafts **(follicular miniaturization)** with increased apoptosis at the dermal papillae.

As the name implies, androgenetic alopecia is driven by both inherited (polygenic inheritance) and hormonal factors. **Dihydrotestosterone** (DHT) appears to be the primary androgen responsible for hair loss. Although total androgen levels are similar in affected and unaffected men, patients with androgenetic alopecia have a greater effect of DHT due to increased local conversion of testosterone to DHT and increased concentrations of androgen receptors in affected areas of the scalp.

Androgenetic alopecia can be treated with 5-alpha reductase inhibitors (eg, **finasteride**), which **decrease** conversion of testosterone to **DHT** in the tissues. However, by preventing conversion to DHT, they **increase the level of testosterone**, which is then available for conversion to **estradiol** by aromatase. This can lead to mild feminizing effects (eg, gynecomastia) in some patients. Other treatments for androgenetic alopecia include topical minoxidil, a vasodilator that appears to increase the vascularity of the dermal papillae.

(Choices A, B, C, and E) Inhibition of 5-alpha reductase by finasteride lowers DHT formation, leading to higher levels of testosterone and increased conversion to estradiol.

Educational objective:

Treatment	• 5-alpha reductase inhibitors (eg, finasteride)

This patient has **androgenetic alopecia** (often called male pattern hair loss), which presents with **progressive hair loss** at the temples, frontal hairline, and vertex. Androgenetic alopecia is characterized by a shortened anagen hair growth phase in the affected portions of the scalp, leading to shorter, thinner hair shafts **(follicular miniaturization)** with increased apoptosis at the dermal papillae.

As the name implies, androgenetic alopecia is driven by both inherited (polygenic inheritance) and hormonal factors. **Dihydrotestosterone** (DHT) appears to be the primary androgen responsible for hair loss. Although total androgen levels are similar in affected and unaffected men, patients with androgenetic alopecia have a greater effect of DHT due to increased local conversion of testosterone to DHT and increased concentrations of androgen receptors in affected areas of the scalp.

Androgenetic alopecia can be treated with 5-alpha reductase inhibitors (eg, **finasteride**), which **decrease** conversion of testosterone to **DHT** in the tissues. However, by preventing conversion to DHT, they **increase the level of testosterone**, which is then available for conversion to **estradiol** by aromatase. This can lead to mild feminizing effects (eg, gynecomastia) in some patients. Other treatments for androgenetic alopecia include topical minoxidil, a vasodilator that appears to increase the vascularity of the dermal papillae.

(Choices A, B, C, and E) Inhibition of 5-alpha reductase by finasteride lowers DHT formation, leading to higher levels of testosterone and increased conversion to estradiol.

Educational objective:
Androgenetic alopecia causes hair loss primarily at the anterior scalp and vertex. It shows polygenic inheritance, with dihydrotestosterone (DHT) being the primary pathogenic factor. Five-alpha reductase inhibitors decrease the conversion of testosterone to DHT and are effective for treating the condition.

References

- The efficacy and safety of 5 α-reductase inhibitors in androgenetic alopecia: a network meta-analysis and benefit-risk assessment of finasteride and dutasteride.

Pharmacology	Dermatology	Hair loss
Subject	System	Topic

Clinical features

- Hair loss at temporal, frontal, vertex scalp

Exhibit Display

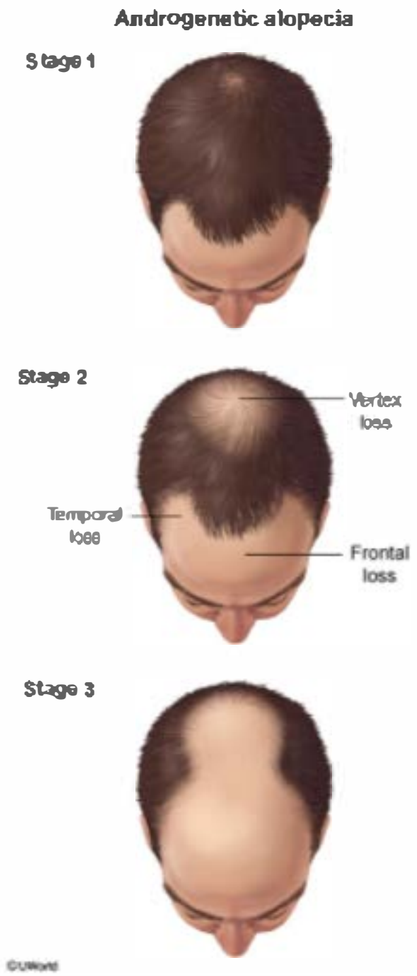

Zoom In | Zoom Out | Reset | Add To New Card | Existing Card

finasteride and dutasteride.

Clinical features • Hair loss at temporal, frontal, vertex scalp

Exhibit Display

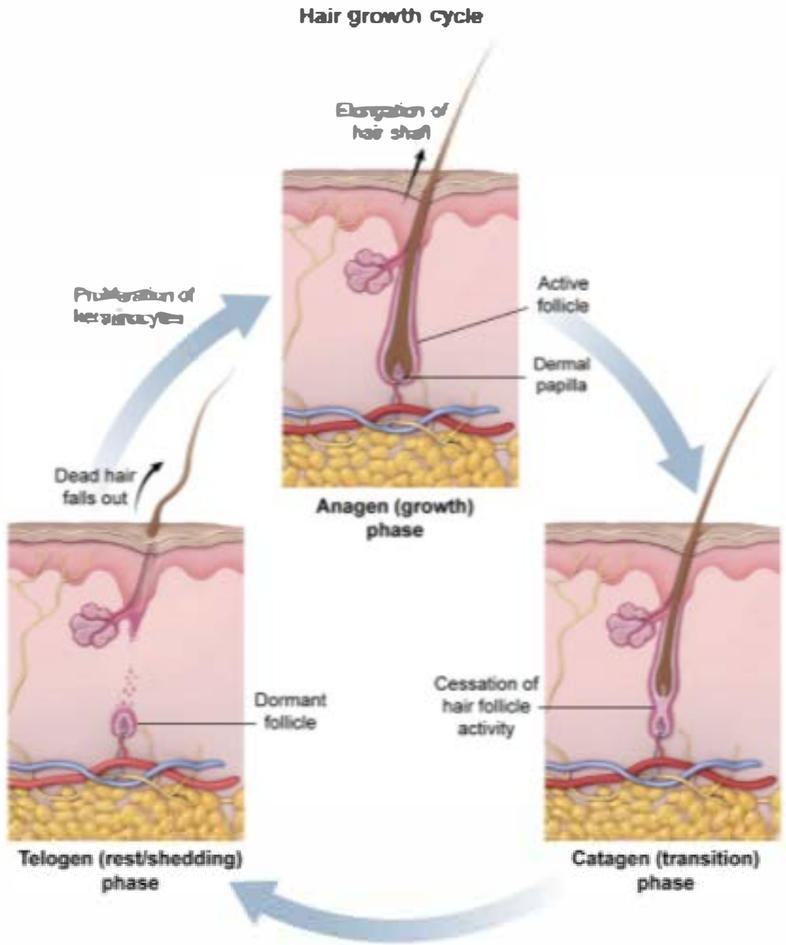

Zoom In | Zoom Out | Reset | Add To New Card | Existing Card

finasteride and dutasteride.

Clinical features
- Hair loss at temporal, frontal, vertex scalp

Exhibit Display

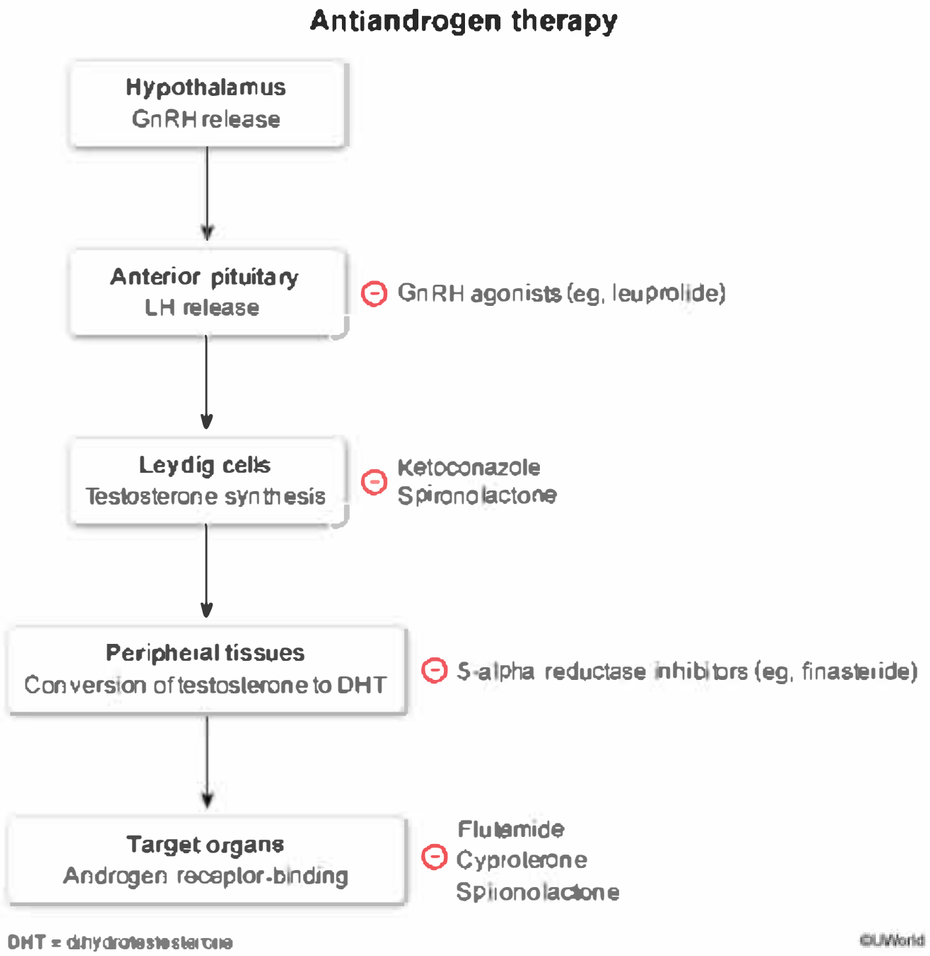

Zoom In | Zoom Out | Reset | Add To New Card | Existing Card

finasteride and dutasteride.

A 31-year-old male farm worker comes to the physician complaining of an itchy rash on his chest. Physical examination reveals an annular and scaling plaque five centimeters in diameter with central clearing on the chest. KOH preparation of skin scrapings shows branching septate hyphae, and topical application of terbinafine was prescribed. Which of the following mechanisms of action explains the antifungal activity of this drug?

A. Binding to ergosterol

B. Inhibition of squalene epoxidase

C. Blocking β-D-glucan synthesis

D. Preventing mitosis by binding tubulin

E. Inhibition of fungal protein synthesis

Submit

A 31-year-old male farm worker comes to the physician complaining of an itchy rash on his chest. Physical examination reveals an annular and scaling plaque five centimeters in diameter with central clearing on the chest. KOH preparation of skin scrapings shows branching septate hyphae, and topical application of terbinafine was prescribed. Which of the following mechanisms of action explains the antifungal activity of this drug?

A. Binding to ergosterol (15%)

✓ B. Inhibition of squalene epoxidase (59%)

C. Blocking β-D-glucan synthesis (7%)

D. Preventing mitosis by binding tubulin (8%)

E. Inhibition of fungal protein synthesis (9%)

Omitted
Correct answer
B

59%
Answered correctly

02 secs
Time Spent

02/03/2020
Last Updated

Explanation

The patient described in this vignette is presenting with symptoms of tinea corporis. Clinically tinea corporis presents as an annular scaling plaque with well-demarcated, raised erythematous borders and central clearing.

Terbinafine is a commonly used drug for treatment of dermatophytosis. It belongs to the class of antifungals called allylamines and may be used topically or orally. Terbinafine inhibits synthesis of ergosterol of the fungal membrane by inhibiting the enzyme squalene epoxidase. Ergosterol is a cell membrane sterol that is unique to fungi and does not occur in human cell membranes. This drug tends to accumulate in skin and its

Explanation

The patient described in this vignette is presenting with symptoms of tinea corporis. Clinically tinea corporis presents as an annular scaling plaque with well-demarcated, raised erythematous borders and central clearing.

Terbinafine is a commonly used drug for treatment of dermatophytosis. It belongs to the class of antifungals called allylamines and may be used topically or orally. Terbinafine inhibits synthesis of ergosterol of the fungal membrane by inhibiting the enzyme squalene epoxidase. Ergosterol is a cell membrane sterol that is unique to fungi and does not occur in human cell membranes. This drug tends to accumulate in skin and its appendages, and its side effects are mild by the topical route.

(Choice A) Binding to ergosterol is a mechanism of action of polyene antifungals (amphotericin B and nystatin).

(Choice C) Caspofungin belongs to the echinocandin class of antifungals. It blocks synthesis of β(1,3)-D-glucan, a main component of *Candida* and *Aspergillus* cell walls.

(Choice D) Griseofulvin binds to polymerized microtubules and disrupts the fungal mitotic spindle, thus preventing fungal cell mitosis. It accumulates in the skin and its appendages and is only effective in dermatophytosis.

(Choice E) Flucytosine is an antimetabolite antifungal that is transformed into 5-fluorouracil in the fungal cell. It inhibits fungal protein synthesis by replacing uracil with 5-fluorouracin in fungal mRNA. It is used in systemic fungal infections.

Educational Objective:
Terbinafine is used for treatment of dermatophytosis. It inhibits synthesis of fungal membrane ergosterol by suppressing the enzyme squalene epoxidase.

Pharmacology	Dermatology	Tinea
Subject	System	Topic

Copyright © UWorld. All rights reserved.

A 27-year-old man comes to the office for evaluation of a rash on both knees. The patient first noticed the rash 2 months ago. He has no other medical conditions and takes no medications. The patient smokes a half pack of cigarettes daily. Vital signs are normal. His knee is shown in the image below:

Removal of the scale results in small bleeding points. As part of the treatment regimen, a topical vitamin D analog is prescribed. This medication is most likely to improve this patient's condition via which of the following mechanisms?

A. Decreased activity of tyrosinase enzyme

B. Decreased levels of irritating fatty acids

C. Increased production of dermal cytokines

D. Inhibition of dermal cyclooxygenase

E. Inhibition of keratinocyte proliferation

Submit

Removal of the scale results in small bleeding points. As part of the treatment regimen, a topical vitamin D analog is prescribed. This medication is most likely to improve this patient's condition via which of the following mechanisms?

A. Decreased activity of tyrosinase enzyme (3%)

B. Decreased levels of irritating fatty acids (3%)

C. Increased production of dermal cytokines (3%)

D. Inhibition of dermal cyclooxygenase (4%)

✓ E. Inhibition of keratinocyte proliferation (84%)

Omitted
Correct answer

84%
Answered correctly

06 secs
Time Spent

03/23/2020
Last Updated

Pathophysiology of psoriasis

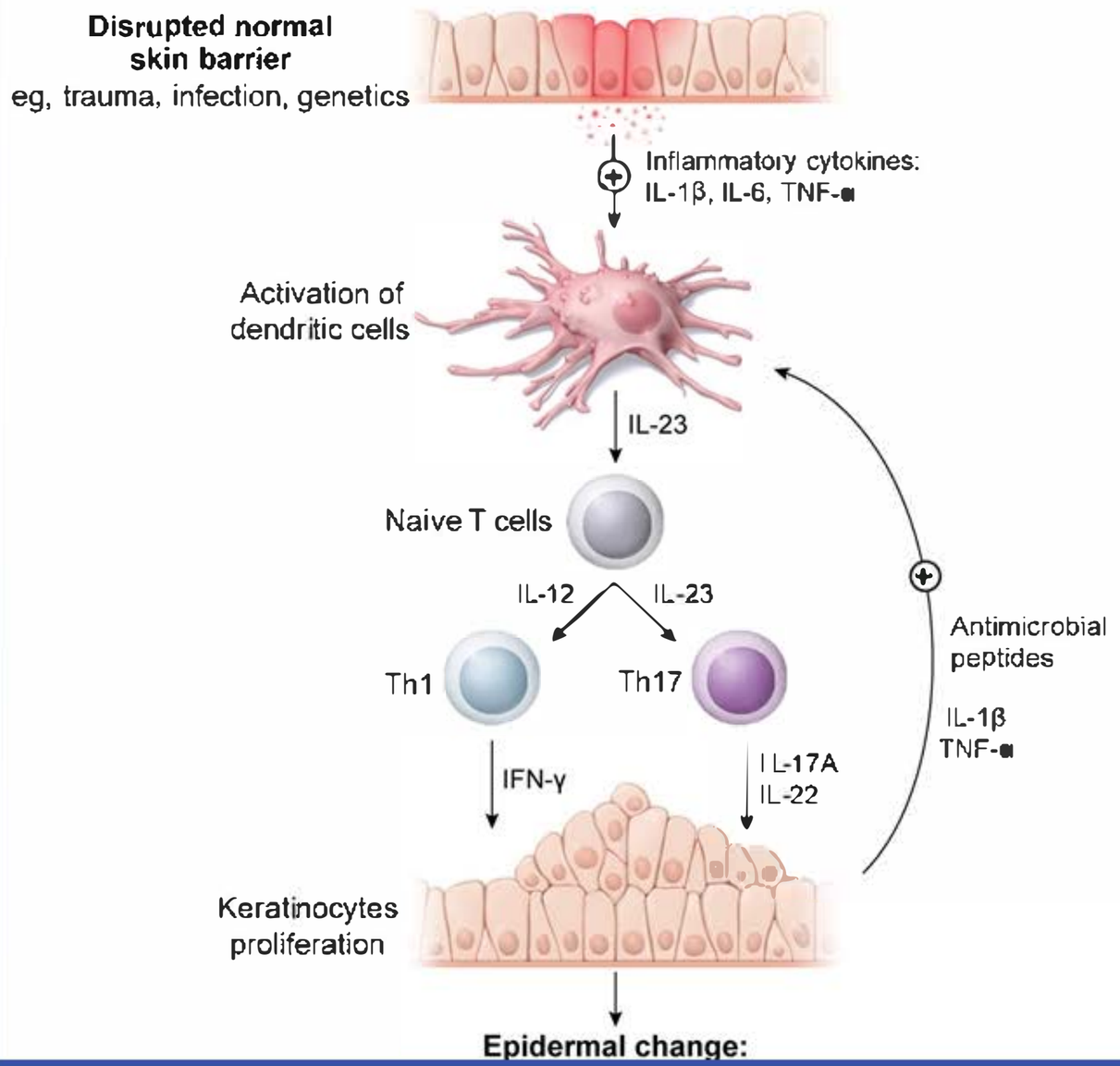

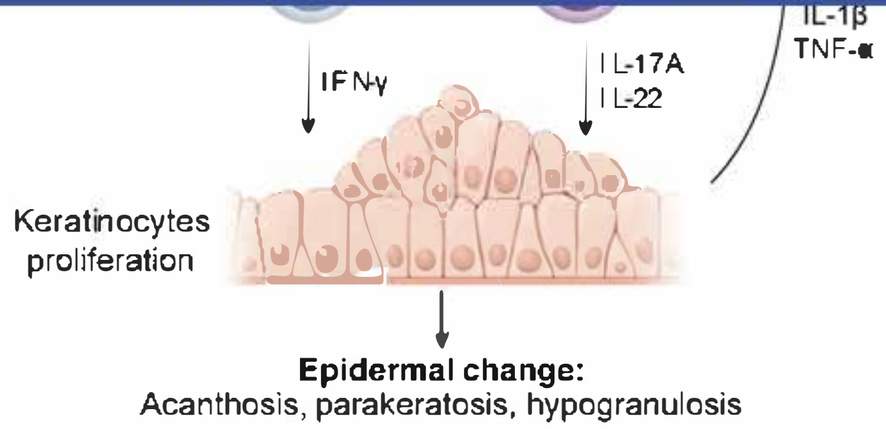

IFN = interferon; IL = interleukin; TNF = tumor necrosis factor.
©UWorld

This patient has **psoriasis**, a common skin disorder characterized by activation of T helper cells and proliferation of keratinocytes. Epidermal hyperplasia (acanthosis) produces **erythematous plaques**, and hyperkeratosis and confluent parakeratosis of the stratum corneum produce the characteristic **scaling**. The epidermal cell layer superficial to the dermal papillae may be thinned and contain dilated blood vessels, which can lead to **pinpoint bleeding** when the scale is removed (Auspitz sign).

First-line treatment options for localized psoriasis include topical **corticosteroids** (eg, diflorasone) and **vitamin D analogs** (eg, calcipotriene, calcitriol). Vitamin D analogs activate the vitamin D receptor, a nuclear transcription factor, resulting in inhibition **of T-cell and keratinocyte proliferation** and stimulation of keratinocyte differentiation. Corticosteroids also have anti-inflammatory and antiproliferative properties; their mechanism of action is complementary to vitamin D analogs, and the 2 agents work well in combination.

(Choice A) Tyrosinase is the primary enzyme responsible for oxidation of tyrosine, which serves as the rate-limiting step in synthesis of melanin. Tyrosinase inhibitors (eg, hydroquinone) decrease synthesis of melanin and can be used in treatment of hyperpigmentation disorders (eg, melasma).

(Choice B) Acne vulgaris is promoted by proinflammatory fatty acid production by *Cutibacterium* (*Propionibacterium*) *acnes*. Benzoyl peroxide has bacteriostatic properties against *C acnes* and reduces production of these inflammatory fatty acids.

(Choice C) Cutaneous warts are the most common manifestation of human papillomavirus infection. Imiquimod is a topical immunomodulator

First-line treatment options for localized psoriasis include topical **corticosteroids** (eg, diflorasone) and **vitamin D analogs** (eg, calcipotriene, calcitriol). Vitamin D analogs activate the vitamin D receptor, a nuclear transcription factor, resulting in **inhibition of T-cell and keratinocyte proliferation** and stimulation of keratinocyte differentiation. Corticosteroids also have anti-inflammatory and antiproliferative properties; their mechanism of action is complementary to vitamin D analogs, and the 2 agents work well in combination.

(Choice A) Tyrosinase is the primary enzyme responsible for oxidation of tyrosine, which serves as the rate-limiting step in synthesis of melanin. Tyrosinase inhibitors (eg, hydroquinone) decrease synthesis of melanin and can be used in treatment of hyperpigmentation disorders (eg, melasma).

(Choice B) Acne vulgaris is promoted by proinflammatory fatty acid production by *Cutibacterium* (*Propionibacterium*) *acnes*. Benzoyl peroxide has bacteriostatic properties against *C acnes* and reduces production of these inflammatory fatty acids.

(Choice C) Cutaneous warts are the most common manifestation of human papillomavirus infection. Imiquimod is a topical immunomodulator that likely induces local cytokine (eg, interferon-alpha, interleukin-6) production against the virus.

(Choice D) Prostaglandin E_2 (which is produced by cyclooxygenase2) is involved in mediating the tumorigenic effects of ultraviolet light in the skin, promoting the formation of actinic keratosis (AK) and squamous cell carcinoma. Topical diclofenac, a nonsteroidal anti-inflammatory drug that inhibits cyclooxygenase, can be used to treat AK.

Educational objective:

First-line treatment options for localized psoriasis include high-potency topical corticosteroids and vitamin D analogs. Vitamin D analogs inhibit T-cell and keratinocyte proliferation and stimulate keratinocyte differentiation. Corticosteroids also have anti-inflammatory and antiproliferative properties; their mechanism of action is complementary to the vitamin D analogs.

References

- Update on pharmacologically-relevant vitamin D analogues.

Pharmacology	Dermatology	Psoriasis
Subject	System	Topic

Copyright © UWorld. All rights reserved.

A 26-year-old male with a history of childhood dermatitis, asthma, and hay fever has routinely been applying a corticosteroid cream to the flexor areas of his skin for many years. The treated areas have remained free of erythema, papules, vesicles, crusts, or scales. A punch biopsy from one of the areas subjected to this topical therapy would most likely show which of the following?

A. Intraepidermal vesicles

B. Epidermal hyperkeratosis

C. Epidermal hyperplasia

D. Dermal atrophy

E. Dermal perivascular lymphocytosis

F. Adipose tissue hyperplasia

Submit

A 26-year-old male with a history of childhood dermatitis, asthma, and hay fever has routinely been applying a corticosteroid cream to the flexor areas of his skin for many years. The treated areas have remained free of erythema, papules, vesicles, crusts, or scales. A punch biopsy from one of the areas subjected to this topical therapy would most likely show which of the following?

- A. Intraepidermal vesicles (3%)
- B. Epidermal hyperkeratosis (16%)
- C. Epidermal hyperplasia (7%)
- ✓ D. Dermal atrophy (58%)
- E. Dermal perivascular lymphocytosis (6%)
- F. Adipose tissue hyperplasia (7%)

Omitted
Correct answer
D

58%
Answered correctly

02 secs
Time Spent

02/03/2020
Last Updated

Explanation

This patient has been successfully treated for atopic eczematous dermatitis. Hence, marked histological manifestations of active eczema such as intraepidermal vesicles, superficial epidermal hyperkeratosis producing scales, epidermal hyperplasia (acanthosis), and/or a chronic inflammatory infiltrate within the dermis would not be expected. This dermatitis cure comes with a price, however; along with anti-inflammatory actions, corticosteroids decrease the production of extracellular matrix collagen and glycosaminoglycans. Consequences include atrophy of the dermis with loss of dermal collagen, drying, cracking, and/or tightening of the skin. Telangiectasias, ecchymoses from mild trauma, and atrophic striae may also be found.

F. Adipose tissue hyperplasia (7%)

Omitted
Correct answer
D

58%
Answered correctly

02 secs
Time Spent

02/03/2020
Last Updated

Explanation

This patient has been successfully treated for atopic eczematous dermatitis. Hence, marked histological manifestations of active eczema such as intraepidermal vesicles, superficial epidermal hyperkeratosis producing scales, epidermal hyperplasia (acanthosis), and/or a chronic inflammatory infiltrate within the dermis would not be expected. This dermatitis cure comes with a price, however; along with anti-inflammatory actions, corticosteroids decrease the production of extracellular matrix collagen and glycosaminoglycans. Consequences include atrophy of the dermis with loss of dermal collagen, drying, cracking, and/or tightening of the skin. Telangiectasias, ecchymoses from mild trauma, and atrophic striae may also be found.

(Choice F) Via an uncertain mechanism, chronic application of topical corticosteroids may also cause atrophy, not hyperplasia, of subcutaneous tissues, including adipocytes.

Educational Objective:
Local cutaneous adverse effects of chronic topical corticosteroid administration include atrophy/thinning of the dermis that is associated with loss of dermal collagen, drying, cracking, and/or tightening of the skin, telangiectasias, and ecchymoses.

Pharmacology	Dermatology	Atopic dermatitis
Subject	System	Topic

Copyright © UWorld. All rights reserved.

A 26-year-old male presents to clinic complaining of a persistent "skin rash." He is a minor league baseball player and practices outdoors for long hours. He chews tobacco and drinks alcohol on weekends. He says he is otherwise healthy. Physical examination reveals a comedonal and inflammatory nodular eruption on the patient's face, chest, and back. Which of the following is the most likely cause of this patient's skin findings?

A. Ephedrine

B. Methyltestosterone

C. Chewing tobacco

D. Ultraviolet light

E. Excessive perspiration

Submit

A 26-year-old male presents to clinic complaining of a persistent "skin rash." He is a minor league baseball player and practices outdoors for long hours. He chews tobacco and drinks alcohol on weekends. He says he is otherwise healthy. Physical examination reveals a comedonal and inflammatory nodular eruption on the patient's face, chest, and back. Which of the following is the most likely cause of this patient's skin findings?

- A. Ephedrine (1%)
- ✓ B. Methyltestosterone (56%)
- C. Chewing tobacco (2%)
- D. Ultraviolet light (17%)
- E. Excessive perspiration (22%)

Omitted
Correct answer
B

56%
Answered correctly

02 secs
Time Spent

05/18/2020
Last Updated

Explanation

This patient has nodular and comedonal acne in his twenties, an age when most patients have outgrown the acne associated with the pubertal androgen surge. Because this patient is an aspiring professional athlete, the possibility of anabolic steroid use must be considered. Anabolic steroids (eg, methyltestosterone) are androgens. Four major elements underlie the pathophysiology of acne: 1) follicular epidermal hyperproliferation; 2) excessive sebum production; 3) inflammation; and 4) *Propionibacterium acnes*. After conversion to dihydrotestosterone, androgens promote both follicular epidermal hyperproliferation and excessive sebum production. Other drugs known to cause acneiform eruptions include epidermal growth factor receptor inhibitors and lithium.

(Choice A) Ephedrine is a sympathomimetic agent related to methamphetamine. It is used to treat bronchial asthma and as a stimulant, appetite

Correct answer
B

Answered correctly

Time Spent

Last Updated

Explanation

This patient has nodular and comedonal acne in his twenties, an age when most patients have outgrown the acne associated with the pubertal androgen surge. Because this patient is an aspiring professional athlete, the possibility of anabolic steroid use must be considered. Anabolic steroids (eg, methyltestosterone) are androgens. Four major elements underlie the pathophysiology of acne: 1) follicular epidermal hyperproliferation; 2) excessive sebum production; 3) inflammation; and 4) *Propionibacterium acnes*. After conversion to dihydrotestosterone, androgens promote both follicular epidermal hyperproliferation and excessive sebum production. Other drugs known to cause acneiform eruptions include epidermal growth factor receptor inhibitors and lithium.

(Choice A) Ephedrine is a sympathomimetic agent related to methamphetamine. It is used to treat bronchial asthma and as a stimulant, appetite suppressant, and decongestant. Androgens are the more likely cause of this patient's acne.

(Choice C) Chewing tobacco is associated with dental caries, gingivitis, oral leukoplakia, and oral cancer.

(Choice D) Ultraviolet light exposure predisposes to skin cancer and exacerbates some dermatoses (eg, lupus, dermatomyositis, pellagra, polymorphous light eruption). Photo-exacerbated dermatoses are not typically associated with acneiform eruptions.

(Choice E) Excessive perspiration exacerbates but does not cause acne.

Educational objective:
Androgens stimulate follicular epidermal hyperproliferation and excessive sebum production, thereby promoting acne development. Anabolic steroid misuse is a known cause of acne, especially in competitive athletes.

Pharmacology	Dermatology	Androgenic steroids
Subject	System	Topic

Copyright © UWorld. All rights reserved.

A 17-year-old girl comes to the office due to worsening acne. The patient's acne had been well controlled with oral doxycycline therapy. However, over the past month, the acne has worsened on her face and back. The patient was recently diagnosed with iron deficiency anemia due to abnormal uterine bleeding and began taking a combined oral contraceptive and an iron supplement. Physical examination shows comedones and pustules on her face and upper back. The remainder of the examination shows no abnormalities. Which of the following is the most likely cause of this patient's worsening symptoms?

A. Adverse effect of the hormonal therapy

B. Bacterial resistance to the antibiotic

C. Decreased absorption of the antibiotic

D. Increased clearance of the antibiotic

E. Increased protein binding of the antibiotic

Submit

A 17-year-old girl comes to the office due to worsening acne. The patient's acne had been well controlled with oral doxycycline therapy. However, over the past month, the acne has worsened on her face and back. The patient was recently diagnosed with iron deficiency anemia due to abnormal uterine bleeding and began taking a combined oral contraceptive and an iron supplement. Physical examination shows comedones and pustules on her face and upper back. The remainder of the examination shows no abnormalities. Which of the following is the most likely cause of this patient's worsening symptoms?

A. Adverse effect of the hormonal therapy (26%)

B. Bacterial resistance to the antibiotic (4%)

✓ C. Decreased absorption of the antibiotic (48%)

D. Increased clearance of the antibiotic (11%)

E. Increased protein binding of the antibiotic (9%)

Omitted
Correct answer
C

48%
Answered correctly

03 secs
Time Spent

02/06/2020
Last Updated

Explanation

Chelation drug interactions	
Mechanism	• Formation of insoluble compounds with polyvalent cations in the gastrointestinal tract • Decreased absorption of drug

Chelation drug interactions	
Mechanism	• Formation of insoluble compounds with polyvalent cations in the gastrointestinal tract • Decreased absorption of drug
Commonly involved drugs	• Tetracyclines • Fluoroquinolones • Levothyroxine
Chelation cations	• Iron • Calcium • Magnesium • Aluminum

This young patient with acne had a good initial response to tetracycline (eg, doxycycline) therapy. However, after the initiation of new medications, she experienced a significant loss of effectiveness, suggesting a possible **drug-drug interaction**. In this case, it is likely that the **new iron supplement** is interacting with tetracycline to cause **decreased absorption** of the antibiotic.

Tetracyclines interact with **polyvalent cations** to form **nonabsorbable chelate complexes** in the gastrointestinal tract. This effect is prominently seen with iron and is also common with other polyvalent metals (eg, aluminum, calcium, magnesium) found in widely used over-the-counter preparations (eg, antacids). Other drugs susceptible to chelation include fluoroquinolones and thyroxine.

The extent of chelation is influenced by gastric pH; the introduction of medications that raise gastric pH (eg, H2-blockers [eg, famotidine], proton pump inhibitors [eg, omeprazole]) can sometimes lead to increased chelation and loss of drug effect. Chelation can often be avoided by taking the medications at different times of the day.

(Choice A) Combination oral contraceptives suppress androgenic activity and reduce production of sebum. This typically leads to improvement, rather than worsening, of acne.

(Choice B) Clinically significant resistance to tetracyclines is uncommon in acne and unlikely to occur abruptly. In addition, besides antimicrobial

This young patient with acne had a good initial response to tetracycline (eg, doxycycline) therapy. However, after the initiation of new medications, she experienced a significant loss of effectiveness, suggesting a possible **drug-drug interaction**. In this case, it is likely that the **new iron supplement** is interacting with tetracycline to cause **decreased absorption** of the antibiotic.

Tetracyclines interact with **polyvalent cations** to form **nonabsorbable chelate complexes** in the gastrointestinal tract. This effect is prominently seen with iron and is also common with other polyvalent metals (eg, aluminum, calcium, magnesium) found in widely used over-the-counter preparations (eg, antacids). Other drugs susceptible to chelation include fluoroquinolones and thyroxine.

The extent of chelation is influenced by gastric pH; the introduction of medications that raise gastric pH (eg, H2-blockers [eg, famotidine], proton pump inhibitors [eg, omeprazole]) can sometimes lead to increased chelation and loss of drug effect. Chelation can often be avoided by taking the medications at different times of the day.

(Choice A) Combination oral contraceptives suppress androgenic activity and reduce production of sebum. This typically leads to improvement, rather than worsening, of acne.

(Choice B) Clinically significant resistance to tetracyclines is uncommon in acne and unlikely to occur abruptly. In addition, besides antimicrobial effects, tetracyclines have anti-inflammatory effects in acne that would likely provide residual benefit.

(Choice D) Tetracyclines such as doxycycline and tigecycline are eliminated by hepatic excretion. Neither iron nor oral contraceptives would increase drug elimination.

(Choice E) Estrogens increase the synthesis of sex hormone–binding globulin, which can affect plasma levels of certain steroid hormones and related agents (eg, danazol, levonorgestrel). Tetracyclines are not significantly affected.

Educational objective:
Tetracyclines interact with polyvalent cations (eg, iron, calcium, aluminum, magnesium) to form nonabsorbable chelate complexes in the gastrointestinal tract. This can lead to significantly decreased drug absorption and therapeutic effect. Fluoroquinolones and thyroxine are also susceptible to chelation.

Pharmacology	Dermatology	Drug interaction
Subject	System	Topic

A 25-year-old previously healthy man comes to the office due to penile lesions. The patient first noticed a nontender papule on his penis a month ago, and it has progressively increased in size and number. He reports no fever, dysuria, or penile discharge. The patient is sexually active with multiple partners and uses condoms inconsistently. Physical examination reveals 3 soft, flesh-colored, papillary lesions measuring <1 cm on the dorsum of the penis. There are no enlarged inguinal lymph nodes, and the remainder of the examination is normal. Treatment is started with a topical agent that acts as a toll-like receptor agonist to increase antiviral cytokine production. Which of the following medications was most likely prescribed to this patient?

A. Calcipotriene

B. Imiquimod

C. Pimecrolimus

D. Salicylic acid

E. Silver nitrate

Submit

A 25-year-old previously healthy man comes to the office due to penile lesions. The patient first noticed a nontender papule on his penis a month ago, and it has progressively increased in size and number. He reports no fever, dysuria, or penile discharge. The patient is sexually active with multiple partners and uses condoms inconsistently. Physical examination reveals 3 soft, flesh-colored, papillary lesions measuring <1 cm on the dorsum of the penis. There are no enlarged inguinal lymph nodes, and the remainder of the examination is normal. Treatment is started with a topical agent that acts as a toll-like receptor agonist to increase antiviral cytokine production. Which of the following medications was most likely prescribed to this patient?

- A. Calcipotriene (14%)
- ✓ B. Imiquimod (43%)
- C. Pimecrolimus (25%)
- D. Salicylic acid (11%)
- E. Silver nitrate (4%)

Omitted
Correct answer
B

Collecting Statistics

02 secs
Time Spent

07/06/2020
Last Updated

Explanation

Imiquimod mechanism of action

Imiquimod

Imiquimod mechanism of action

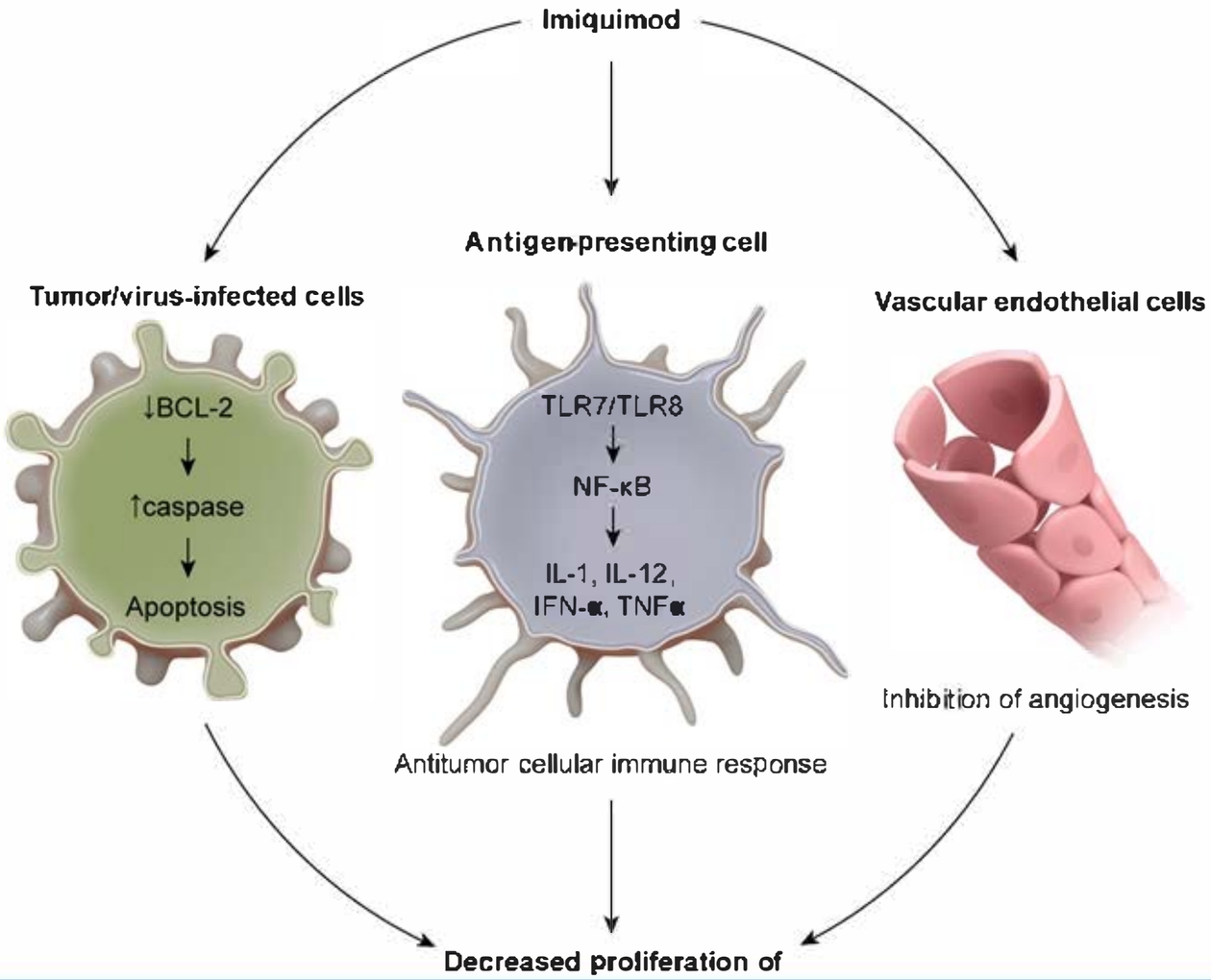

Imiquimod is a topical immunomodulatory drug that is used to treat many common dermatologic disorders associated with abnormal cell proliferation, including anogenital warts (ie, human papillomavirus infection), superficial basal cell carcinoma, and actinic keratosis. The antiviral and **antiproliferative** effects of imiquimod are primarily mediated through activation of **toll-like receptor 7**, which upregulates the proinflammatory transcription factor nuclear factor-kappa B **(NF-κB)**.

NF-κB increases transcription of proinflammatory genes, activating antigen-presenting cells (eg, Langerhans cells in the skin) and initiating an immune response involving natural killer cells, cytotoxic T cells, and **type 1 helper T cells**. This results in **increased cytokine production** (eg, IL-1, IL-12, interferon-alfa/gamma, tumor necrosis factor-alpha) and enhanced immune-mediated killing of aberrant cells (eg, cancer cells, virus-infected cells).

Other antiproliferative effects of imiquimod include:

- Induction of **apoptosis** of aberrant cells through **caspase activation** via inhibition of BCL-2
- **Inhibition of angiogenesis** by downregulating proangiogenic factors (eg, fibroblast growth factor) and upregulating angiogenesis inhibitors (eg, interferon-gamma, IL-12)

(Choice A) Calcipotriene is a vitamin D analog (ie, activates the vitamin D receptor, a nuclear transcription factor) used to treat plaque psoriasis. It acts by inhibiting T-cell and keratinocyte proliferation and stimulating keratinocyte differentiation.

(Choice C) Pimecrolimus is a calcineurin inhibitor used to treat atopic dermatitis (eczema). It acts by blocking the translocation of NFAT (nuclear factor of activated T cells), resulting in reduced transcription of IL-2.

(Choice D) Topical salicylic acid is a keratolytic agent that acts by increasing sloughing of virus-infected epidermal cells. It is widely used to treat common warts but is not recommended for anogenital warts.

(Choice E) Silver nitrate is a caustic agent that coagulates cellular proteins to form an eschar. It is used to cauterize wounds to stop bleeding (eg, epistaxis) and to remove excess granulation tissue.

Educational objective:
Imiquimod is a widely used topical immunomodulatory agent that stimulates a potent cellular and cytokine-based immune response to aberrant cells (eg, human papillomavirus-infected cells in anogenital warts) by activating toll-like receptors and upregulating NF-κB. Other antiproliferative effects of imiquimod include inhibition of angiogenesis and induction of apoptosis.

immune response involving natural killer cells, cytotoxic T cells, and **type 1 helper T cells**. This results in **increased cytokine production** (eg, IL-1, IL-12, interferon-alfa/gamma, tumor necrosis factor-alpha) and enhanced immune-mediated killing of aberrant cells (eg, cancer cells, virus-infected cells).

Other antiproliferative effects of imiquimod include:

- Induction of **apoptosis** of aberrant cells through **caspase activation** via inhibition of BCL-2
- **Inhibition of angiogenesis** by downregulating proangiogenic factors (eg, fibroblast growth factor) and upregulating angiogenesis inhibitors (eg, interferon-gamma, IL-12)

(Choice A) Calcipotriene is a vitamin D analog (ie, activates the vitamin D receptor, a nuclear transcription factor) used to treat plaque psoriasis. It acts by inhibiting T-cell and keratinocyte proliferation and stimulating keratinocyte differentiation.

(Choice C) Pimecrolimus is a calcineurin inhibitor used to treat atopic dermatitis (eczema). It acts by blocking the translocation of NFAT (nuclear factor of activated T cells), resulting in reduced transcription of IL-2.

(Choice D) Topical salicylic acid is a keratolytic agent that acts by increasing sloughing of virus-infected epidermal cells. It is widely used to treat common warts but is not recommended for anogenital warts.

(Choice E) Silver nitrate is a caustic agent that coagulates cellular proteins to form an eschar. It is used to cauterize wounds to stop bleeding (eg, epistaxis) and to remove excess granulation tissue.

Educational objective:
Imiquimod is a widely used topical immunomodulatory agent that stimulates a potent cellular and cytokine-based immune response to aberrant cells (eg, human papillomavirus-infected cells in anogenital warts) by activating toll-like receptors and upregulating NF-κB. Other antiproliferative effects of imiquimod include inhibition of angiogenesis and induction of apoptosis.

Pharmacology	Dermatology	Imiquimod
Subject	System	Topic

Copyright © UWorld. All rights reserved.